



Contents lists available at: <https://amejcaserepclinimag.com/>

American Journal of Case Reports and Clinical Images



Severe Hyperglycaemia with Concomitant Asymptomatic Covid-19 Infection: A Case Report

Jacek Kleszczyński¹, Iryna Boliukh², Agnieszka Rombel-Bryzek², Rafał J. Bułdak²



¹Emergency Department, Institute of Medical Sciences, University of Opole, Opole, Poland.

²Department of Clinical Biochemistry and Laboratory Diagnostics, Institute of Medical Sciences, University of Opole, Opole, Poland.

ARTICLE INFO

Article history:

Received: 09-09-2025

Revised: 20-09-2025

Accepted: 25-09-2025

Published: 30-09-2025

KEY WORDS:

Diabetic Ketoacidosis,

Hyperglycaemic Hyperosmolar.

ABSTRACT

Background: Acute hyperglycaemic crises, such as diabetic ketoacidosis (DKA) and hyperosmolar hyperglycaemic state (HHS), are serious and potentially life-threatening complications of diabetes that can also be triggered by viral infections.

Case Report: A 64-year-old woman was admitted to the hospital emergency department because of syncope and impaired consciousness that began the previous day. The patient had experienced polydipsia, polyuria, and weight loss over the past four weeks. Laboratory results revealed a serum glucose concentration of 2362.2 mg/dL. A positive RT-PCR test for SARS-CoV-2 was also documented. Finally, the patient was diagnosed with hyperglycaemic-hyperosmolar syndrome (HHS), hypokalaemia and nonketotic metabolic acidosis. Hyperglycaemia was treated with an insulin bolus, followed by continuous infusion under glucose monitoring. The patient received also multi-electrolyte solution therapy.

Conclusion: COVID-19 infection may significantly influence blood glucose levels. During the diagnostic evaluation and treatment of hyperglyceridaemia, clinicians should remain vigilant for the potential diagnosis of DKA and/or HHS.

Copyrights © 2025, Jacek Kleszczyński, et al., This article is licensed under the Creative Commons Attribution-Non-Commercial-4.0-International-License-(CCBY-NC) (<https://amejcaserepclinimag.com/blogpage/copyright-policy>). Usage and distribution for commercial purposes require written permission.

Introduction

Acute hyperglycaemic crises, such as diabetic ketoacidosis (DKA) and hyperosmolar hyperglycaemic state (HHS), constitute serious and potentially life-threatening complications of diabetes, which may also be initiated by viral infections. DKA is recognized as a serious metabolic disorder associated with the accumulation of ketone bodies and the development of acidosis. It occurs most frequently in patients with type 1 diabetes mellitus (T1DM), although it can also appear in patients with type 2 diabetes mellitus (T2DM), particularly during viral infections [1].

A mixed form, referred to as DKA-HHS, has also been described in the literature. It is characterized by the coexistence of features of both conditions and is associated with a more severe clinical course and higher mortality [2,3]. Research findings suggest that SARS-CoV-2 infection may increase the risk of developing both DKA and HHS. A potential underlying mechanism involves the acceleration of lipolysis and the induction of ketosis in the course of COVID-19 [4–7].

Despite the growing number of observations, knowledge regarding acute metabolic decompensation in the form of DKA and HHS in patients with diabetes and concomitant COVID-19 infection remains limited. Therefore, further research is of particular importance, especially regarding the classification criteria of both syndromes, the assessment of their relative contribution to the clinical course, and the verification of the accuracy of

diagnostic and prognostic markers in the context of SARS-CoV-2 infection. It is also essential to determine the extent to which different supportive therapeutic strategies translate into treatment outcomes.

In this article, we present the case of a patient with a severe acute hyperglycaemic crisis and concomitant SARS-CoV-2 infection, and we discuss the applied therapeutic approach, the analysis of which may help to better understand the pathophysiology of this complex clinical condition.

Case Report

A 64-year-old woman with a history of nephrosclerosis and recurrent exacerbations of chronic kidney disease (CKD) was admitted to the hospital emergency department because of syncope and impaired consciousness that began the previous day. At the time of admission, the patient was in a coma with a Glasgow Coma Scale (GCS) score of 10. The heart rate was 120/min., blood pressure 130/79 mmHg, and Kussmaul-type rapid respiration. The patient had experienced polydipsia, polyuria, and weight loss over the past four weeks. The jugular veins were not visible and capillary refill was 3 seconds. The abdomen was soft but tender to palpation. In addition, signs of dehydration were observed. It was not possible to determine the blood glucose level with the glucometer (the message HIGH was displayed). Imaging studies were ordered, including an abdominal X-ray and a non-contrast CT scan of the head, along with laboratory tests and an RT-PCR test for SARS-CoV-2. Laboratory results revealed a serum glucose concentration of 2362.2 mg/dL (Figure 1), hyperemia with an increased MCV, leukocytosis with neutrophilia, and lymphopenia: Hct 54.7%, Hg 16.10 g/dL, RBC 6.40 M/ μ L, MCV 101.30 fL, WBC 13.07 K/ μ L (NEU% 91.00, LYM%

* Corresponding author.

Jacek Kleszczyński, Emergency Department, Institute of Medical Sciences, University of Opole, Oleska 48, 45052 Opole, Email: jacek.kleszczyński@uni.opole.pl.

3.10, MONO% 5.70), PLT 269.00 K/ μ L. Glycosuria of approximately 125 mg/dL was detected. The glycosylated hemoglobin (HbA1c) level exceeded 14%, indicating chronic severe hyperglycemia. An increase in creatinine concentration to 2.68 mg/dL due to severe dehydration. Arterial blood gas analysis revealed a pH of 7.31, pCO₂ of 38 mmHg, and pO₂ of 177 mmHg, with sodium concentration of 140 mmol/L, potassium 2.6 mmol/L, chloride 111 mmol/L, bicarbonate (HCO₃⁻) 18.8 mmol/L, base excess -6.5 mmol/L. The lactate concentration was 3.6 mmol/L. Tests performed upon admission also showed elevated levels of liver enzymes with normal bilirubin concentration, hyperproteinemia with hypoalbuminemia, and elevated inflammatory markers: ALAT 105.0 U/L, AspAT 54.0 U/L, GGTP 164.0 U/L, total bilirubin 1.10 mg/dL, total protein 5.6 g/dL, albumin 2.6 g/dL, CRP 139.2 mg/L, and procalcitonin 0.44 ng/mL. Finally, the patient was diagnosed with hyperglycemic-hyperosmolar syndrome (HHS), hypokalemia and nonketotic metabolic acidosis (Table 1). The treatment of hyperglycemia was initiated with an intravenous bolus of insulin at 0.1 IU/kg of body weight (a total of 4-8 IU). Subsequently, insulin therapy was continued with a continuous intravenous infusion of 2-4 IU/h, under glucose level monitoring (Figure 1).

The patient received multi-electrolyte solution therapy (MES) according to the following protocol: 1 liter of fluid in the first hour, followed by 500 ml/h over the next 5 hours. After reaching a blood glucose level of 1000 mg/dL, MES was replaced with a fluid consisting of a 0.9% NaCl solution and a 5% glucose solution in an equivalent ratio. Thromboprophylaxis was initiated, along with potassium supplementation at a rate of 25 mmol/h using a potassium chloride (KCl) solution. After 6 hours of treatment, the woman regained consciousness (GCS14), but remained in serious general conditions. Due to elevated markers of inflammation, empirical antibiotic therapy was initiated (amoxicillin with clavulanic acid at a dose 1.2 g every 8 hours intravenously). On the fourth day of hospitalization, the patient's condition significantly improved. No disturbances in consciousness or signs of dehydration were observed, and abdominal tenderness on palpation subsided. Blood glucose levels decreased, metabolic acidosis resolved, creatinine levels normalized, and inflammatory markers also declined. Insulin therapy was switched from continuous infusion to subcutaneous administration. A repeat PCR test for SARS-CoV-2 on the fifth day of hospitalization was positive, despite the absence of symptoms indicative of COVID-19 infections. Consequently, the

patient, in good general condition, was transferred to a facility specializing in the treatment of COVID-19 patients with further recommendations.

Discussion

The report presents the case of a woman with a blood glucose level of 2362.2 mg/dL. In the search for the cause of such severe hyperglycemia, a coexisting SARS-CoV-2 infection was considered, as previous studies have shown that the occurrence of diabetic ketoacidosis (DKA) and hyperosmolar hyperglycemic state (HHS) may be the first manifestation of SARS-CoV-2 infection in patients with diabetes [4-7]. In the present case, a positive RT-PCR test for SARS-CoV-2 was also documented. Given the markedly elevated level of glyated hemoglobin, it is highly probable that SARS-CoV-2 infection exacerbated the patients hyperglycemia and played a direct role in the development of HHS.

One of the diagnostic challenges involves differentiating between DKA and HHS, as the pathogenesis of these conditions follows a very similar course. However, the presence of residual insulin in HHS prevents ketogenesis and almost completely inhibits hepatic lipolysis, which is responsible for the development of DKA [8]. A combined DKA-HHS syndrome has also been described, exhibiting features of both conditions and associated with a more severe clinical course and higher mortality rates [2,3]. In recent years, the measurement of end-tidal carbon dioxide (etCO₂) has been introduced in the diagnostic evaluation of HHS and DKA; however, this technique still requires further validation through randomized studies [9].

It is crucial to emphasize the need for prompt investigation in patients with HHS, given its high mortality rate (10-15%) [8,10]. COVID-19 infection has been frequently identified as an independent risk factor contributing to increased mortality and a higher incidence of complications in patients with diabetes [5]. Nonetheless, individuals presenting with HHS demonstrated more favorable clinical outcomes compared to those with DKA [6].

Conclusion

In summary, COVID-19 infection may significantly influence blood glucose levels. During the diagnostic evaluation and treatment of hyperglycemia, clinicians should remain vigilant for the potential diagnosis of DKA and/or HHS. The high rate of complications and considerable mortality associated with these conditions underscore the

Table 1: Hyperglycaemic-hyperosmolar syndrome - diagnostic criteria and parameter values in the patient.

Diagnostic criteria	Recognition values	Parameter values in the patient
Glycemia	> 600 mg/dL	2362.2 mg/dL
Blood pH	> 7.3	7.31
HCO ₃	> 15 mmol/L	18.8 mmol/L
Ketone bodies	no	no
Effective osmolality	> 320 mOsm/kg H ₂ O	357 mOsm/kg H ₂ O

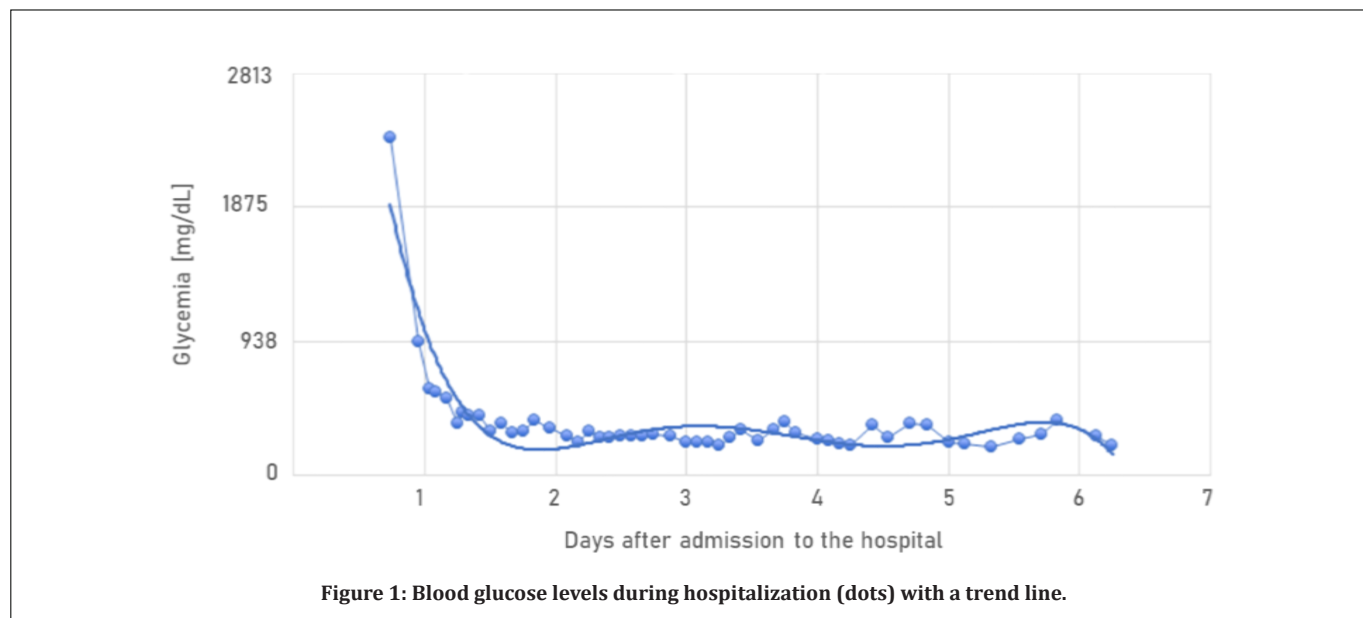


Figure 1: Blood glucose levels during hospitalization (dots) with a trend line.

Jacek Kleszczyński, Iryna Bolikh, Agnieszka Rombel-Bryzek, Rafal J. Budlak (2025). Severe Hyperglycaemia with Concomitant COVID-19 Infection: A Case Report. American Journal of Case Reports and Clinical Images, 2(2), 01-03.

urgent need for further randomised controlled trials and well-designed cohort studies.

Financial Support: None declared.

Conflicts of Interest: None declared.

Ethical Consideration: Not Required.

References

1. Li J, Wang X, Chen J, Zuo X, Zhang H, Deng A. COVID-19 infection may cause ketosis and ketoacidosis. *Diabetes Obes Metab* 2020;22:1935-1941.
2. Naranjo JMA, Larrondo EFH, Arroyo MGS. Combined diabetic ketoacidosis and hyperosmolar hyperglycemic state associated with COVID 19. *J Endocr Soc* 2021;5:A372-A373.6
3. Pasquel FJ, Tsegka K, Wang H, Cardona S, Galindo RJ, Fayfman M, et al. Clinical outcomes in patients with isolated or combined diabetic ketoacidosis and hyperosmolar hyperglycemic state: A retrospective, hospital-based cohort study. *Diabetes Care* 2019;43:349-357.7
4. Pal R, Banerjee M, Yadav U, Bhattacharjee S. Clinical profile and outcomes in COVID-19 patients with diabetic ketoacidosis: A systematic review of literature. *Diabetes Metab Syndr Clin Res Rev* 2020;14:1563-1569.1
5. Hasan SS, Kow CS, Bain A, Kavanagh S, Merchant HA, Hadi MA. Pharmacotherapeutic considerations for the management of diabetes mellitus among hospitalized COVID-19 patients. *Expert Opin Pharmacother* 2021;22:229-240.2
6. Papadopoulos VP, Koutroulos MV, Zikoudi DG, Bakola SA, Avramidou P, Touzlatzi N, Filippou DK. Acute metabolic emergencies in diabetes and COVID-19: a systematic review and meta-analysis of case reports. *Diabetol Int* 2021;12:445-459.3
7. Kim N, Ha E, Moon JS, Lee YH, Choi EY. Acute hyperglycemic crises with coronavirus disease-19: Case reports. *Diabetes Metab J* 2020;44:349-353.4
8. Umpierrez GE. Hyperglycemic crises: Diabetic ketoacidosis and hyperglycemic hyperosmolar state. In: Bonora E, DeFronzo RA, editors. *Diabetes complications, comorbidities and related disorders*. Endocrinology. Cham: Springer International Publishing; 2020. p.595-614.5
9. Bhattaram S, Shinde VS, Khumujam PP, Anilkumar AP, Reddy DK. Capnography as a tool for triaging and diagnosis of diabetic ketoacidosis in the emergency department: A prospective observational study. *Turk J Emerg Med* 2023;23:169-175.8
10. Fayfman M, Pasquel FJ, Umpierrez GE. Management of hyperglycemic crises: Diabetic ketoacidosis and hyperglycemic hyperosmolar state. *Med Clin North Am* 2017;101:587-606.9

Jacek Kleszczyński, Tryna Bolukh, Agnieszka Rombel-Byzek, Rafał J. Budałak (2025). Severe Hyperglycaemia with Concomitant Asymptomatic COVID-19 Infection: A Case Report. *Severe Hyperglycaemia with Concomitant COVID-19. American J Case Rep Clin Imag*. 2025; September, 2(2), 01-03.



Submit your manuscript to the

American Journal of Case Reports and Clinical Images
CODEN: USA

and benefit from:

- Convenient online submission
- Rigorous peer review
- Immediate publication on acceptance
- Open access: articles freely available online
- High visibility within the field
- Retaining the copyright to your article

Submit your manuscript at

<https://amejcaserepclinimag.com/>
&

wjcasereports@gmail.com; submission@amejcaserepclinimag.com