



Contents lists available at <https://amejcaserepclinimag.com/>

# American Journal of Case Reports and Clinical Images



## Surgical Management of Congenital Transdiaphragmatic Hernia with Abdominal Wall Involvement in an Adult: A Case Report

<sup>1</sup>Muhammad Shaheer Saleem, <sup>1</sup>Wen-Zhang Zha, <sup>1</sup>Yong Zhou, <sup>1</sup>Fu-Ming Xuan, <sup>3</sup>Samia Abbas, <sup>2</sup>Hamza Maqbool, <sup>1</sup>Madni Abbas

<sup>1</sup>General Surgery Department, Yancheng 1st People's Hospital, Affiliated Hospital of Xuzhou Medical University, Yancheng 224000, Jiangsu Province, China

<sup>2</sup>Neurology Department, Yancheng 1st People's Hospital, Affiliated Hospital of Xuzhou Medical University, Yancheng 224000, Jiangsu Province, China



### ARTICLE INFO

#### Article history:

Received: 12-03-2024  
Revised: 15-04-2024  
Accepted: 21-04-2024  
Published: 28-04-2024

#### KEY WORDS:

Transdiaphragmatic intercostal hernia,  
Abdominal wall hernia,  
Pleural effusion,  
Atelectasis,  
Surgical management. Case report

### ABSTRACT

**BACKGROUND:** Congenital Transdiaphragmatic Hernia (CTDH) in adults is rare, often presenting with abdominal wall hernias, which complicates diagnosis and treatment. This case report discusses a 56-year-old male with intermittent upper abdominal discomfort, pleural effusion, and respiratory distress. CT scans identified a transdiaphragmatic intercostal hernia with pleural complications. Emergency intervention revealed necrotic omentum and high pleural fluid volume, highlighting the diagnostic complexity and need for prompt management in CTDH patients.

**AIM:** To determine the diagnostic and therapeutic approach for CTDH in adults with abdominal wall hernia and pleural complications.

**METHODS:** A case study was conducted in a hospital setting on a 56-year-old male presenting with symptoms of abdominal discomfort and respiratory distress. Contrast-enhanced CT imaging identified CTDH and abdominal wall hernia, with pleural effusion and atelectasis. The patient underwent emergency laparotomy, drainage of 2500 ml pleural fluid, hernia sac repair, and pleural drainage. Recovery was assessed with follow-up imaging to monitor resolution of pleural and pulmonary conditions.

**RESULTS:** Emergency laparotomy revealed an incarcerated, necrotic omentum within the hernia sac, which was surgically removed. Approximately 2500 ml of dark pleural fluid was drained, and pleural drainage was performed. Post-surgery, the patient experienced significant recovery with full restoration of lung function and no postoperative complications. Follow-up imaging confirmed resolution of pleural effusion and atelectasis, demonstrating successful surgical intervention and recovery.

**CONCLUSION:** Early diagnosis and individualized surgery are critical in managing adult CTDH, reducing risk of organ strangulation and respiratory failure.

**Copyrights** © 2024, Zha Wen Zhang, et al. This article is licensed under the Creative Commons Attribution-Non-Commercial-4.0-International-License-(CCBY-NC) (<https://amejcaserepclinimag.com/blogpage/copyright-policy>). Usage and distribution for commercial purposes require written permission.

### Core Tip:

This report examines a rare adult case of Congenital Transdiaphragmatic Hernia (CTDH) in a 56-year-old with abdominal wall hernia and pleural effusion. Early CT imaging provided critical insights into the hernias and respiratory complications. Emergency laparotomy, including hernia repair and pleural drainage, led to successful resolution. This case underscores the necessity of prompt, individualized surgical intervention to prevent life-threatening complications like organ strangulation, especially in patients with elevated BMI, which heightens intra-abdominal pressure. The findings highlight the need for early detection and multidisciplinary management in adult CTDH cases.

#### \* Corresponding author:

Zha Wen Zhang, Fracs, PhD, Full Professor, General Surgery, Yancheng First People HOSPITAL, No.166, Yulong West Road, Tinghu Yancheng Jiangsu China, Yancheng 224000, Jiangsu Province, China, Email: wenzhang@sina.cn; Yong Zhou, PhD, General Surgery, Yancheng First People Hospital, No.166, Yulong West Road, Tinghu Yancheng Jiangsu China, Yancheng 224000, Jiangsu Province, China, Email: zhouyong13616@sina.com

### INTRODUCTION

The concurrent occurrence of transdiaphragmatic intercostal hernia with an abdominal wall hernia is an exceptionally rare clinical presentation, further complicated by its association with pleural effusion and atelectasis. The case under study involves a congenital rupture of the right intercostal muscle, leading to the separation of the ribs and disruption of the diaphragm, which caused herniation of abdominal contents into both the thoracic cavity and subcutaneously through the abdominal wall [1]. This form of hernia is categorized as a transdiaphragmatic intercostal hernia or, in some instances, an abdominal intercostal hernia [2].

Structural defects of the diaphragm can arise due to various factors, including traumatic injury or congenital anomalies during fetal development. Typically, congenital diaphragmatic hernias (CDH) are detected in infancy due to respiratory distress; however, it is possible for some cases to remain asymptomatic and undiagnosed until adulthood. In

such cases, the diagnosis is often delayed, leading to further complications such as organ strangulation and respiratory impairment. The case under study offers unique insights into the spontaneous prolapse of abdominal organs through the chest wall, known as spontaneous transdiaphragmatic intercostal hernia or intercostal pleuroperitoneal hernia, a condition rarely documented in the literature [3].

The complexity of this case lies not only in the rarity of the dual hernia presentation but also in the diagnostic challenges it poses. The association of pleural effusion and atelectasis in such cases raises the stakes for timely and accurate intervention, as the delay in treatment can lead to significant respiratory compromise[4]. This report provides a thorough analysis of the patient’s clinical presentation, diagnostic approach, surgical intervention, and postoperative recovery, with particular emphasis on the management of complications arising from pleural effusion and atelectasis. The case also underscores the critical importance of a multidisciplinary approach in managing complex hernias, where prompt surgical intervention is often the definitive treatment to prevent life-threatening complications.

**Case Report**

**Chief Complaints and History of Present Illness**

A 56-year-old male developed intermittent discomfort in the right upper abdomen, without apparent triggers, approximately 15 days prior to presentation. The discomfort was accompanied by an increase in the local skin temperature of the abdominal wall, but there was no radiation to other areas. During this period, there was no associated nausea, vomiting, chills, fever, dizziness, headache, hematemesis, or melena. Initial treatment at a local hospital, including anti-inflammatory and rehydration therapy, did not lead to significant improvement. On the 15th day of illness, the patient, who had previously experienced only intermittent abdominal pain without any respiratory issues, suddenly

developed severe shortness of breath due to the onset of pleural effusion. No oxygen therapy was administered, except for bed elevation to assist breathing. This acute change in symptoms prompted an emergency surgical intervention on the same day.

**Physical Examination**

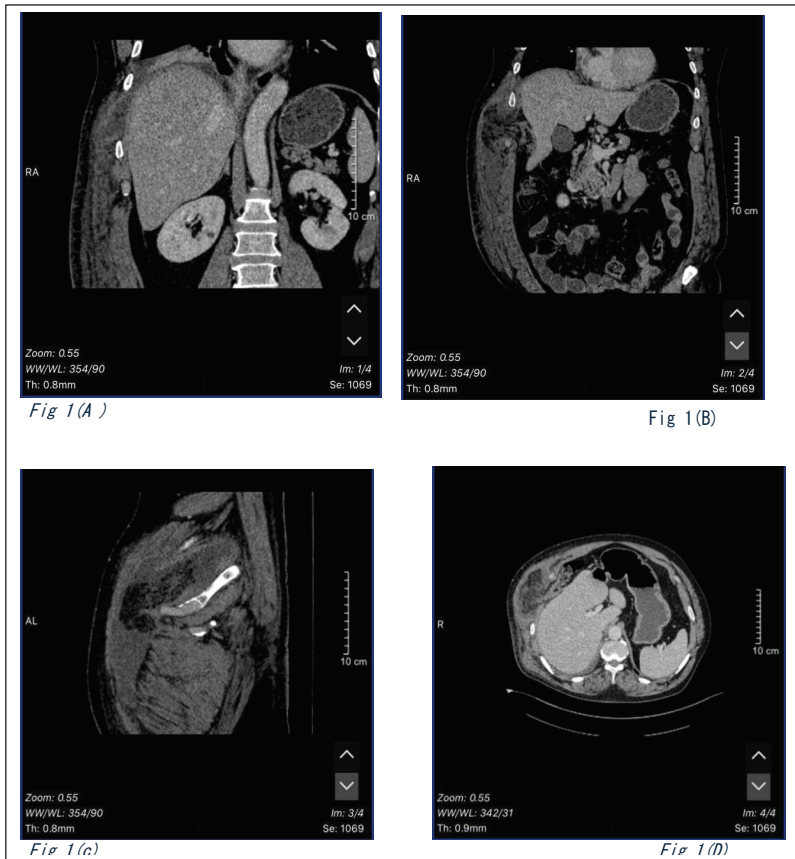
Prior to performing the CT scan, chest X-rays and ultrasound were considered. However, given the complexity of the patient’s condition and the suspected involvement of both thoracic and abdominal structures, CT was prioritized for its superior diagnostic capacity. A CT scan revealed the presence of a right upper abdominal wall hernia with localized exudation and effusion. The scan also indicated right pleural effusion with insufficient lung expansion (atelectasis). Based on these findings, the patient was admitted with a suspected abdominal wall hernia.

The patient’s BMI was 34.5, which likely contributed to increased intra-abdominal pressure, exacerbating both the transdiaphragmatic intercostal hernia and the abdominal wall hernia. Elevated pressure may have facilitated the herniation of the abdominal organs, leading to complications such as pleural effusion and atelectasis. The patient reported no significant medical history, including hypertension, diabetes, coronary heart disease, surgeries, or trauma. He had no history of contact with confirmed or suspected cases of pneumonia and had not traveled recently. He denied smoking and alcohol use.

**Laboratory and Imaging Findings**

Physical examination revealed decreased breath sounds in the lower right lung field, and a non-tender mass was palpable on the right lower chest wall. Vital signs were within normal limits. Respiratory assessment showed normal abdominal breathing and no abnormalities in the intercostal spaces. Upon percussion, both lungs were dull, but no pleural friction or subcutaneous crepitus was detected. Auscultation revealed clear breath sounds without rales or pleural rubs, and speech conduction was

Muhammad Shaheer Saleem, Wen-Zhang Zha, Yong Zhou, Fu-Ming Xuan, Samia Abbas, Hamza Maqbool, Madni Abbas, (2024), Surgical Management of Congenital Transdiaphragmatic Hernia with Abdominal Wall Involvement in an Adult: A Case Report. American J Case Rep Clin Imag, 2024; 1(1):1-5



**Figure 1:** (A): Coronal CT abdomen image shows a soft tissue window at the diaphragm level, highlighting a large collection along the right lateral abdominal wall, communicating with the right pleural cavity through a likely defect in the diaphragm at its attachment to the lower ribs at the costophrenic angle. Small pleural effusion and basal atelectasis are also visible. (B) Coronal CT abdomen image reveals an anterior wall defect with omentum as hernial content and a large inter-muscular collection along the right anterolateral wall. (C) Sagittal CT abdomen image displays a collection communicating with the right pleural space and extending to the lateral abdominal wall. (D) Axial CT abdomen image shows a right lateral abdominal wall defect with herniated omentum as its content.

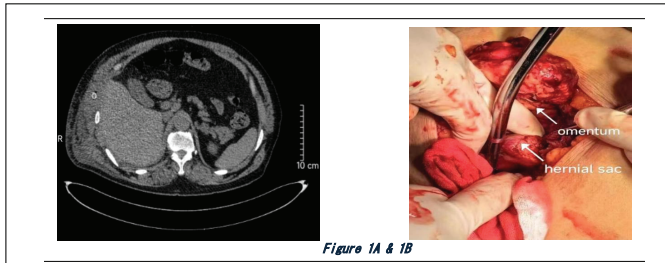


Figure 1A & 1B

**Figure 2:** (A) Post-operative Axial CT abdomen image showing the right lateral abdominal wall defect that has been now repaired with a drain in situ. Few air specks (iatrogenic) are noted. The abdomen soft tissue window showed resolution of right pleural effusion and the diaphragmatic intra-thoracic hernia has been repaired. Figure 2 (B) image taken during operation showing herniated omentum and hernial sac.

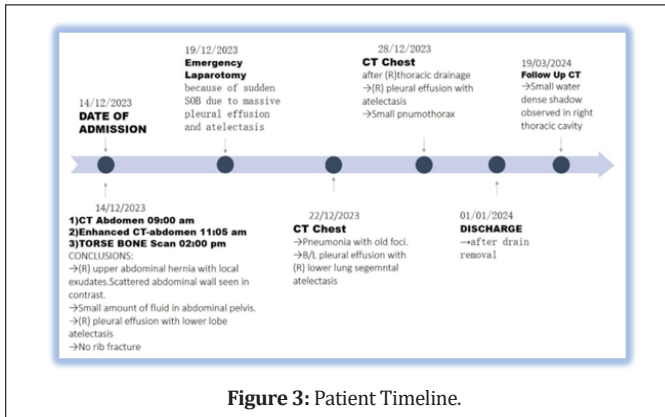


Figure 3: Patient Timeline.

unremarkable. The abdomen was soft and flat, with no palpable mass, but tenderness was noted in the right upper quadrant without rebound tenderness. The liver was not palpable. Laboratory findings were within normal limits.

Following the CT scan findings, ultrasound imaging was conducted to further assess the pleural effusion and cardiac function. Ultrasound confirmed the presence of pleural effusion, which contributed to compromised lung function. This was evidenced by the decrease in lung expansion on the right side, correlating with the atelectasis observed. The strain on the heart was minimal, as suggested by the relatively normal ejection fraction and dimensions of the cardiac chambers.

A 3D reconstruction of the ribs via CT imaging did not reveal any fractures. However, patchy consolidation was observed in the lower lobe of the right lung. The hilar structures were clear, and there was no mediastinal shift. A fluid-density shadow was seen on the right side of the chest. Additionally, the soft tissue of the right abdominal wall appeared significantly swollen, with localized weakness suggestive of an abdominal wall hernia. A repeat CT scan, performed two days after admission, confirmed a hernia of the right upper abdominal wall with associated exudation, effusion, and swelling. There was also possible infection, calcification of the right lobe of the liver, and persistent right pleural effusion with insufficient lung expansion secondary to the mass effect from the hernias. Additionally, right cardiophrenic angle lymph node enlargement was noted.

The patient remained under observation while awaiting surgery. On the fifth day of admission, he developed sudden dyspnea due to massive pleural effusion and right lower lobe atelectasis, necessitating an emergency laparotomy. Following the successful induction of anesthesia, the patient was positioned supine on the operating table, and standard aseptic preparations were carried out. A 10 cm incision was made approximately 2 cm below and parallel to the costal margin, directly over the visible hernia. The subcutaneous tissues were carefully dissected and exposed. Upon opening the hernia sac, approximately 2500 ml of dark, black fluid was drained. The pus was aspirated to expose the hernia sac neck.

Intraoperative findings revealed that the transdiaphragmatic hernia contained an incarcerated and strangulated portion of the omentum, which had herniated from the junction of the diaphragm and peritoneum into the lateral abdominal wall. The hernia sac was in direct communication with the chest cavity, and a significant amount of pleural effusion was present, compressing approximately half of the right lung. The necrotic

portion of the omentum was excised, and the remaining omentum and colon wall were examined, with no further abnormalities identified.

**Final Diagnosis**

The patient was diagnosed with Congenital Transdiaphragmatic Hernia (CTDH) with associated abdominal wall hernia, complicated by right-sided pleural effusion, atelectasis, and incarceration of necrotic omentum. The elevated intra-abdominal pressure, likely exacerbated by the patient’s BMI, contributed to the herniation and subsequent respiratory compromise.

Considering the patient’s symptoms and diagnostic results, the surgical intervention included repair of the transdiaphragmatic hernia, partial omentectomy, and chest drainage. The omentum was repositioned into the abdominal cavity, and the diaphragm was repaired using 1-5 absorbable sutures, with each layer meticulously sutured. The operation proceeded smoothly, with satisfactory anesthesia and a postoperative improvement in the patient’s pulse and oxygen saturation levels. Intraoperative blood loss was estimated at 50 ml

**Postoperative Course:**

The patient’s postoperative recovery was smooth, with a steady improvement in respiratory function and the resolution of both pleural effusion and atelectasis. A follow-up CT scan confirmed the successful repair of the hernias, and the patient experienced significant relief from preoperative symptoms. Pulmonary rehabilitation, along with vigilant monitoring for any recurrence of the hernias, was integrated into the postoperative care plan. On the 13th day post-surgery, the chest drainage tube was removed, and the patient was discharged later that same day in stable condition.

**Discussion**

Adult Congenital Transdiaphragmatic Hernia (CTDH) accompanied by an Abdominal Wall Hernia is a rare and complex condition, particularly in adult patients. The simultaneous presence of both hernias presents significant diagnostic and therapeutic challenges. Diaphragmatic hernias can present acutely, often accompanied by visceral herniation, which leads to severe symptoms such as chest pain and dyspnea[5]. In this case, the omentum was incarcerated and strangulated, but the clinical presentation can vary greatly, depending on the size and contents of the hernia, manifesting as thoracoabdominal pain, respiratory distress, cough, or gastrointestinal symptoms like vomiting [2].

Elevated intra-abdominal pressure due to factors such as obesity or pregnancy can exacerbate the diaphragmatic defect, leading to further herniation of abdominal contents into the thoracic cavity. This phenomenon is well-documented in the literature, where it is noted that such pressure changes can displace organs like the omentum, colon, and stomach into the thorax, particularly in diaphragmatic hernias. Studies suggest that 25% to 50% of congenital diaphragmatic hernias in adults are diagnosed incidentally during imaging for unrelated conditions, which complicates early diagnosis [6]. In patients with underlying conditions such as COPD, the use of corticosteroids is often prescribed for disease management, and these can impair wound healing post-surgery [7]. Though this patient had no history of steroid use, the correlation between obesity, intra-abdominal pressure, and delayed wound healing remains a relevant concern in such cases [8].

Transdiaphragmatic Intercostal Hernia (TDIH) is another rare condition that can develop either acutely or gradually over time. This type of hernia is typically caused by a rupture of both the diaphragm and intercostal muscles, often associated with rib fractures[9]. In this case, no rib fractures were present, but the literature suggests that violent coughing episodes, as documented in several studies, can generate sufficient force to rupture the diaphragm and cause herniation[10]. The protective effect of the liver on the right side of the diaphragm makes right-sided diaphragmatic ruptures less common, yet they carry a higher risk of complications when they occur, including increased morbidity and mortality[8]. This further underscores the complexity of managing such cases, particularly when both respiratory and gastrointestinal symptoms overlap.

To diagnose adult CTDH with Abdominal Wall Hernia, a comprehensive clinical evaluation is essential. The presentation typically includes nonspecific symptoms such as abdominal pain and respiratory difficulty, and the examination often reveals a reducible mass in the lower chest wall, along with a positive cough impulse[11]. A characteristic finding is the fluctuation in the size of the hernia sac during respiration—enlarging on inspiration and shrinking on expiration—suggestive of a diaphragmatic

hernia. Imaging plays a critical role in confirming the diagnosis, with contrast-enhanced CT scans considered the gold standard. However, in resource-limited settings or in cases where CT is unavailable, chest X-rays or ultrasounds can be employed to rule out other conditions [12].

Surgical repair remains the definitive treatment for both CTDH and abdominal wall hernias. Laparotomy is typically performed in emergencies involving diaphragmatic rupture, but minimally invasive techniques such as laparoscopy are becoming viable alternatives, particularly in stable patients. The decision between laparotomy and laparoscopy depends on the patient's overall condition and the surgeon's expertise, with some studies suggesting that laparoscopy results in shorter recovery times and reduced trauma [13]. However, for cases with hemodynamic instability or significant intra-abdominal involvement, laparotomy remains the approach of choice [8]. In cases where herniation involves multiple organs, as seen in this case, an individualized surgical plan must be developed, considering the extent of organ involvement and the potential for complications such as pleural effusion or atelectasis.

In this case, postoperative complications included pleural effusion and atelectasis, primarily due to compromised blood flow to the herniated omentum, leading to necrosis [14]. The connection between the hernia sac and the pleural cavity allowed fluid to accumulate within the pleural space, contributing to the development of atelectasis. Timely postoperative care, including fluid drainage and respiratory support, was crucial in resolving these complications and ensuring a successful recovery [8].

In conclusion, managing the dual presentation of Adult CTDH and Abdominal Wall Hernia requires a tailored, multidisciplinary approach. Prompt imaging, followed by timely surgical intervention, is essential to prevent life-threatening complications such as organ strangulation, pleural effusion, and respiratory distress [15]. The choice of surgical technique should be individualized based on the duration of symptoms, the extent of herniation, and the presence of additional injuries [8,12].

## Conclusion

This case of Congenital Transdiaphragmatic Hernia (CTDH) combined with an Abdominal Wall Hernia, complicated by pleural effusion and atelectasis, provides valuable insights into the management of this rare and complex condition. The successful treatment of such cases requires vigilant clinical assessment, particularly in patients with a history of trauma or surgery. Comprehensive diagnostic imaging and careful surgical planning are paramount to addressing the hernia and preventing further complications. Surgical intervention remains the cornerstone of treatment, tailored to the individual patient's anatomy and clinical presentation. This case highlights the importance of a personalized approach to patient management, where surgical strategies are adapted to the unique features of each hernia. Additionally, this study contributes to the growing body of literature on CTDH, offering insights that may shape future therapeutic strategies for similar presentations.

**Acknowledgments:** The authors would like to acknowledge Muhammad Shaheer Saleem and ZHA WEN ZHANG for their expertise, which contributed significantly to the development of this manuscript. We also thank [any additional individuals, institutions, or departments, if applicable] for their support in providing clinical insights, imaging, or diagnostic assistance. We are grateful to [any reviewers or colleagues, if applicable] for their constructive feedback, which helped enhance the quality of this work.

## Footnotes

**Author Contributions:** Wen-Zhang Zha and Muhammad Shaheer Saleem designed the study and contributed to data interpretation, with Muhammad Shaheer Saleem designated as the co-first author for his equal role in the study's conceptualization and analysis. Yong Zhou and Fu-Ming Xuan assisted with patient data collection and clinical analysis. Hamza Maqbool provided insights and reviewed imaging results. Madni Abbas and Samia Abbas offered support in surgical procedures and radiological assessments, respectively. Muhammad Shaheer Saleem supervised the study, and Wen-Zhang Zha and Yong Zhou served as the primary contact for journal correspondence as the corresponding author. All authors contributed to manuscript drafting and provided final approval for submission.

**Funding:** This research received no specific grant from any funding agency in the public, commercial, or not-for-profit sectors.

**Informed Consent Statement:** The patient, or their legally authorized

representative, provided informed oral consent for inclusion in this case report and for the publication of clinical details and images.

**Ethical Committee:** We get the permission from ethical committee and review board of Yancheng First People Hospital, Affiliated Hospital of Xuzhou Medical University

**Conflict-of-Interest Statement:** All authors report having no relevant conflicts of interest for this article. The authors declare no financial relationships, personal relationships, or other affiliations that could influence the work presented in this case report. Additionally, there were no outside influences or competing interests that impacted the design, data collection, analysis, or interpretation of this study.

**CARE Statement:** The authors have read the CARE checklist of items, and the manuscript was prepared and revised according to the CARE checklist of items.

**Corresponding Author's Membership in Professional Societies:** Dr WEN-CHANG Zha.

**Corresponding Author's Membership in Professional Societies:** 江苏省医学会肝癌专业委员会委员

**Specialty type:** Hepatopancreatobiliary surgery

**Surgery Country/Territory of origin:** China

**Dr Yong Zhou.** Corresponding Author's Membership in Professional Societies: Corresponding Author's Membership in Professional Societies: 中国中医药信息学会中西医外科智能诊疗分会常务理事江苏省胰腺专病质控中心质控对象单位质控主任江苏省医师协会微创专业委员会委员 "International Journal of Clinical Gastroenterology and Hepatology" 杂志编委 "Int J Surg" "安徽医药" 杂志审稿专家

**Specialty type:** Hepatopancreatobiliary surgery

**Surgery Country/Territory of origin:** China

## REFERENCES

1. J. Lee, J. S. Kim, and J. Y. Jeong, "Non traumatic acquired acute transdiaphragmatic intercostal hernia induced by coughing," 2023. doi: 10.1186/s13019-023-02320-3.
2. M. Abu-Gazala, A. Ratnayake, S. Abu-Gazala, and M. Bala, "An enigma of spontaneous combined transdiaphragmatic, intercostal and abdominal wall hernia," *Hernia*, vol. 17, no. 3, 2013, doi: 10.1007/s10029-012-0902-9.
3. K. Lasithiotakis et al., "Incarcerated spontaneous transdiaphragmatic intercostal hernia," *Int J Surg Case Rep*, vol. 2, no. 7, 2011, doi: 10.1016/j.ijscr.2011.07.002.
4. J. C. Rompen, C. J. Zeebregts, R. L. Prevo, and J. M. Klaase, "Incarcerated transdiaphragmatic intercostal hernia preceded by Chilaiditi's syndrome," *Hernia*, vol. 9, no. 2, 2005, doi: 10.1007/s10029-004-0287-5.
5. J. P. Ramspott et al., "Case Report: Adult Right-Sided Bochdalek Hernia Complicated by Intrathoracic Bowel Perforation," *Front Surg*, vol. 8, 2021, doi: 10.3389/fsurg.2021.755279.
6. L. Schumacher and S. Gilbert, "Congenital Diaphragmatic Hernia in the Adult," 2009. doi: 10.1016/j.thorsurg.2009.08.004.
7. C. I. O. Chaar, P. Attanasio, and F. Dettlerbeck, "Disruption of the costal margin with transdiaphragmatic abdominal herniation induced by coughing," *American Surgeon*, vol. 74, no. 4, 2008, doi: 10.1177/000313480807400416.
8. D. Predescu, F. Achim, B. Socea, M. C. Ceaușu, and A. Constantin, "Rare Diaphragmatic Hernias in Adults—Experience of a Tertiary Center in Esophageal Surgery and Narrative Review of the Literature," 2024. doi: 10.3390/diagnostics14010085.
9. Y. S. Wu, Y. Y. Lin, C. W. Hsu, S. J. Chu, and S. H. Tsai, "Massive ipsilateral pleural effusion caused by transdiaphragmatic intercostal hernia," *American Journal of Emergency Medicine*, vol. 26, no. 2, 2008, doi: 10.1016/j.ajem.2007.04.018.
10. S. C. Shanmukhappa, M. A. Malik, N. Akula, and F. Shaikat, "MULTIPLE RIB FRACTURES, PLEURAL EFFUSION AND RIGHT-SIDED

DIAPHRAGMATIC HERNIATION OF THE COLON INTO THE CHEST ASSOCIATED WITH CHRONIC COUGH AFTER COVID-19," Eur J Case Rep Intern Med, vol. 10, no. 3, 2023, doi: 10.12890/2023\_003812.

11. S. L. Siow, C. M. Wong, M. Hardin, and M. Sohail, "Successful laparoscopic management of combined traumatic diaphragmatic rupture and abdominal wall hernia: A case report," J Med Case Rep, vol. 10, no. 1, 2016, doi: 10.1186/s13256-015-0780-8.
12. H. B. Shin and Y.-J. Jeong, "Diagnostic Considerations of Late Presenting Congenital Diaphragmatic Hernia in Children: Single Center Experience," Advances in Pediatric Surgery, vol. 26, no. 1, 2020, doi: 10.13029/aps.2020.26.1.11.
13. M. Giuffrida et al., "Management of complicated diaphragmatic hernia in the acute setting: a WSES position paper," 2023. doi: 10.1186/s13017-023-00510-x.
14. A. Gori, H. Ferland, L. M. Otalvaro Acosta, S. Di Saverio, and G. Velmahos, "Acquired transdiaphragmatic intercostal hernia in a patient with recent pneumonia: surgical management with a thoracoabdominal approach," 2020. doi: 10.1111/ans.15547.
15. E. Smith-Singares, "Thoracoscopic management of a traumatic subacute transdiaphragmatic intercostal hernia. Second case reported," Trauma Case Rep, vol. 28, 2020, doi: 10.1016/j.tcr.2020.100314.

Muhammad Shaheer Saleem, Wen-Zhang Zha, Yong Zhou, Fu-Ming Xuan, Samia Abbas, Hamza Maqbool, Madni Abbas, (2024), Surgical Management of Congenital Transdiaphragmatic Hernia with Abdominal Wall Involvement in an Adult: A Case Report. American J Case Rep Clin Imag. 2024; 1(1)1-5



Submit your manuscript to the

American Journal of Case Reports and Clinical Images  
CODEN: USA

and benefit from:

- Convenient online submission
- Rigorous peer review
- Immediate publication on acceptance
- Open access: articles freely available online
- High visibility within the field
- Retaining the copyright to your article

Submit your manuscript at

<https://amejcaserepclinimag.com/>  
&

[wjcasereports@gmail.com](mailto:wjcasereports@gmail.com); [submission@amejcaserepclinimag.com](mailto:submission@amejcaserepclinimag.com)